

# Original article

## Endovenous laser ablation of great saphenous vein with ultrasound-guided perivenous tumescence: early and midterm results

CHEN Jia-quan, XIE Hui, DENG Hao-yu, YUAN Kai, ZHANG Ji-wei, ZHANG Hao and ZHANG Lan

**Keywords:** endovenous laser ablation; great saphenous vein; occlusion; tumescent anaesthesia

**Background** Endovenous laser ablation (EVLA) is an improved method to treat varicose great saphenous veins (GSV) with a high satisfactory rate. This study aimed to evaluate the efficiency and safety of treatment by EVLA procedures with ultrasound-guided perivenous tumescence.

**Methods** Thirty-one patients (31 limbs) with symptomatic varicose vein primary to chronic venous insufficiency (CVI) treated with EVLA were prospectively studied. The entire procedure was performed under ultrasound-guided tumescent local anesthesia. The patients were evaluated with a 18 month follow-up postoperation using clinical examination and venous duplex ultrasonography. Pain scores and quality of life (QOL) were recorded using visual analog scale (VAS) and the chronic venous insufficiency questionnaire (CIVIQ) at 1 week, 1 month, and 12 months after operation.

**Results** All patients tolerated EVLA procedure well. The overall success occlusion rates of GSV were 92%, 94%, and 94% at 1, 12, and 18 months follow-up, respectively. The score of CIVIQ one week preoperation was  $69.14 \pm 11.44$  while that of CIVIQ one month postoperation was  $85.32 \pm 4.89$ . The life quality has significantly improved after the operation of EVLA ( $t=12.71$ ,  $P < 0.05$ ). The VAS one month after treatment was lower than 1 week before therapy ( $t=8.048$ ,  $P < 0.05$ ). Major complications such as deep vein thrombosis and skin burns were not found. Most of the complications were minor and improved quickly.

**Conclusions** This refinement type of EVLA procedure is a safe and effective treatment with a high satisfaction rate; it displayed noteworthy features including shortening hospitalization, early ambulant activity, and preferable occlusion rates.

*Chin Med J 2013;126 (3): 421-425*

Chronic venous insufficiency (CVI) of the lower limb is the most common cause of varicose veins; it affects and impacts the patient's quality of life (QOL). Although classic intervention of ligation with or without stripping incompetent great saphenous veins (GSV) has an excellent early outcome, in some cases, it promotes significant bleeding and trauma to the saphenous vein track; furthermore the recurrence rate within 5 years is up to 20%–40%.<sup>1</sup>

In the last decade, minimally invasive techniques, such as endovenous laser ablation (EVLA), radiofrequency ablation, and ultrasound guided foam sclerotherapy displayed noteworthy features including shortening hospitalization, early ambulant activity, and excellent cosmetic results.<sup>2,3</sup> In particular, EVLA has been shown to be a highly effective treatment with preferable occlusion rates.<sup>4,5</sup>

As a refinement of EVLA, based on the technique of tumescent anesthesia, we start infusing saline plus adrenaline and lidocaine solution in the saphenous compartment guided by ultrasound before EVLA to minimize bleeding and decrease post-operative discomfort.<sup>6,7</sup> The purpose of this prospective study was to evaluate its safety and effectiveness of this EVLA

procedure.

### METHODS

#### Patients

From March to May 2011, we enrolled 31 symptomatic patients who suffered GSV varicosity and primary saphenofemoral junction (SFJ) insufficiency. Seventeen (54.8%) patients were female, and 14 (45.2%) were male (mean age, 49 years, range, 22–66 years). A single vascular surgeon examined all patients. The principal examination included a detailed history of disease, a focused physical examination, and venous duplex ultrasound imaging. The exclusion criteria included occlusive arterial disease, a known thrombotic disease or hemorrhagic tendency, inactivity to ambulate, and

DOI: 10.3760/cma.j.issn.0366-6999.20122290

Department of Vascular Surgery, Renji Hospital, School of Medicine, Shanghai Jiao Tong University, Shanghai 200127, China (Chen JQ, Xie H, Deng HY, Yuan K, Zhang JW, Zhang H and Zhang L)

Correspondence to: Dr. ZHANG Lan, Department of Vascular Surgery, Renji Hospital, School of Medicine, Shanghai Jiao Tong University, Shanghai 200127, China (Tel: 86-2168383743. Fax: 86-2168383422. Email: lucky200207@sina.cn)

The work was supported by a grant from the Shanghai Committee of Science and Technology, China (No. 10ZR1418800).

pregnancy. Demographic characteristics, clinical characteristics, and clinical etiology anatomy pathophysiology (CEAP) classifications of all patients are listed in Table 1. A family history of varicose veins was present in 15 patients (48.4%).

Informed consent was obtained from the patient and their relatives, and the study was carried out according to the Principles of the *Declaration of Helsinki*.

### Color duplex ultrasonography (CDU)

Venous duplex ultrasonography examination was performed on each patient before and after their therapy (Sonosite, M-Turbo, 5-12 MHz linear probe). Deep, superficial, and perforating venous systems were evaluated with the patient in an upright position. The purpose of the examination before operation was to measure GSV diameter (between 7 and 10 mm), and determine venous reflux, which is defined as retrograde flow with duration of greater than 1.0 seconds. All the patients had no evidence of venous thrombosis and deep venous insufficiency. The postoperative CDU concerned about the ablated vein for venous reflux, thrombus, and recanalization. The success of the ablation procedure was defined as lack of compressibility of the treated GSV segment, absence of blood flow inside the vein, decreased vein diameter, the palpation of the fibrotic vein, and no deep vein thrombosis during examination.

### EVLA and surgical technique

The course of GSV, branch varicosities, and perforating veins were identified by inspection and CDU while the patient was in the upright position, and were marked on the skin with a marking pen. A single surgical team performed all procedures.

EVLA with a 980 nm diode laser (Medilas D Compact, Dornier MedTech, Germany) was performed under tumescent anesthesia<sup>8,9</sup> for all the 31 patients. However 10 patients (32.3%) who had serious lipodermatosclerosis

**Table 1.** Demographic and clinical data of 31 patients who accepted the treatment of EVLA

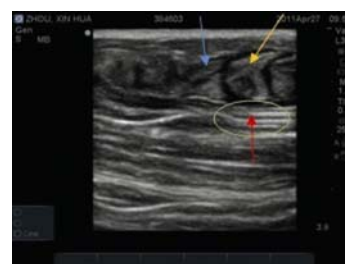Variables	Results
Mean age (years, mean (range))	49 (22–66)
Sex (n (%))	
Male	17 (54.8)
Female	14 (45.2)
Family history (n (%))	15 (48.4)
Previous treatment (n (%))	
Sclerotherapy	8 (25.8)
Phlebectomy	12 (38.7)
Preoperative symptoms (n (%))	
Leg fatigue	4 (12.9)
Pain	17 (54.8)
Cramp	9 (29.0)
Edema	9 (29.0)
CEAP classification before treatment (n (%))	
C2 (simple varicose vein)	1 (3.2)
C3 (ankle edema)	2 (6.5)
C4 (gaiter area discoloration)	28 (90.3)
C5 (healed venous ulcer)	0 (0)

or numerous insufficiency vein tributaries were under tumescent technique along with intradural or general anesthesia to satisfy comfort intraoperation. Of course, the dosage of lidocaine should be decreased in the tumescent solution. The GSV was inserted at knee level via a percutaneous needle puncture (19-gauge, Seldinger technique) under ultrasound guidance. A 4-Fr guiding catheter was then passed over the 0.035-J tip guide wire 3–4 cm below the SFJ. Once we confirmed the position of the sheath with ultrasonography, a 600  $\mu$ m bare-tipped laser fiber was inserted. The distal tip of the laser fiber was positioned 2–3 cm below the SFJ. The entire procedure was performed under ultrasound guidance. In the same session, EVLA was performed without high ligation of GSV.

Then a tumescent local anesthetic solution, which consists of 20 ml 1% lidocaine and adrenaline (1:100 000) diluted in 500 ml of cold (4°C) saline<sup>9</sup> was applied perivenously under ultrasound guidance too. Adrenaline, promoting vasoconstriction of the vein, reduces the incidence of hematoma and hyperpigmentation. A 10-ml syringe with a 19-gauge needle under ultrasound guidance was used for the infusion until collapse of the GSV and a nonechogenic halo were observed around the main trunk of GSV (Figure 1). The tumescent solution surrounding the GSV reduces the incidence of heat damage to surrounding structures. And it induces spasm in the vein so that the energy from the laser is much easily absorbed by the vein wall.<sup>7</sup>

The linear energy density (LEED) values were used to calculate the laser energy based on the GSV diameter, 1.5–2.0 cm distal to SFJ. For GSV diameters between 4.5 and 6.9 mm, 60–70 J/cm of energy was used; for GSV diameters between 7 and 10 mm, 80–90 J/cm of energy was used.<sup>10</sup> Laser energy was delivered endovenously in a continuous plus lipopoly saccharide (LPS) fashion. The laser fiber was slowly withdrawn under ultrasound guidance at a velocity of 1 mm/s until it reached a distance of 2.0–2.5 cm from the puncture site of the GSV at the knee level. At last, it should be confirmed through ultrasound without thrombosis in the SFJ.

Following laser ablation of the GSV from the groin to the knee, we made minimally invasive stab incisions of 2–3 mm over the previously marked branch varicosities and insufficiency perforator vein if necessary. Minimal



**Figure 1.** Intra-operative image by CDU. The lumen of GSV was squashed (green ellipse) by hypodermic oedema, which was caused by injecting tumescent local anesthetic solution (blue arrow). An optical fiber and a catheter were detected by CDFI in

the lumen of GSV (red arrow). A puncture needle can be seen in the hypodermic oedema (yellow arrow).

invasive incisions were closed with Steri-strips. Then, an elastic compression bandage was applied and kept over the length of the treated vein for 48 hours. Then a thigh-high, class II graduated compression stocking (35–40 mmHg) was applied for 4 weeks except when the patients were sleeping or showering.

Aescufen fort was prescribed (300 mg, twice daily, orally), and patients were instructed to use it routinely for 1 month after hospital discharge.

### Quality of life

The Chronic venous insufficiency questionnaire (CIVIQ) was applied to assess the patients' QOL one week before varicose vein surgery (defined as CIVIQ-1) and at least 1 month after treatment (defined as CIVIQ-2). The scale contained four dimensions (20 questions), namely pain, physical dimension, social function, and psychological dimension. There are five grades to each question using 10 cm visual-analog scale (from 1 to 5 points accompany with the serious situation). CIVIQ scores vary from 20 (refer to very poor QOL) to 100 points (very good QOL).<sup>11,12</sup>

### Visual analog scale (VAS)

Following the treatment, all patients were informed and asked to complete a diary card for 7 days to record their level of pain. They were asked to use the VAS (0 cm for no pain and 10 cm for the worst pain possible), which was provided at the time of discharge. At the first postablation follow-up, patients were questioned about whether they took the recommended analgesic drugs and if so, on which day they perceived the maximum amount of pain. Also at the follow-up of 1 month, patients were informed to complete a diary card to record their level of pain again.

### Assessment of outcome

Complications such as ecchymosis, skin burn, paresthesia, induration, or complaints related to EVLA were evaluated and recorded for each case. Subsequent follow-ups, which included clinical examination and venous CDU, were performed at 1 week, 1, 12, and 18 months postoperation to examine the venous reflux and recanalization.

### Statistical analysis

Statistical analysis was performed with GraphPad Prism5 (Graphpad software, USA) statistic software. Continuous variables are reported as mean  $\pm$  standard deviation (SD). Significant differences analysis was performed using the paired *t* test. Significance was accepted for a *P* value of less than 0.05.

## RESULTS

### QOL

All 31 patients completed the CIVIQ-1. At least one month after therapy, CIVIQ-2 was completed by all patients (follow-up rate 100%). The score of CIVIQ-1

was  $69.14 \pm 11.44$  while that of CIVIQ-2 was  $85.32 \pm 4.89$ . The latter was much higher than the former. The life quality has significantly improved after operation of EVLA. Paired *t*-test showed that *t* value was 12.71 with significant differences (*P* < 0.05).

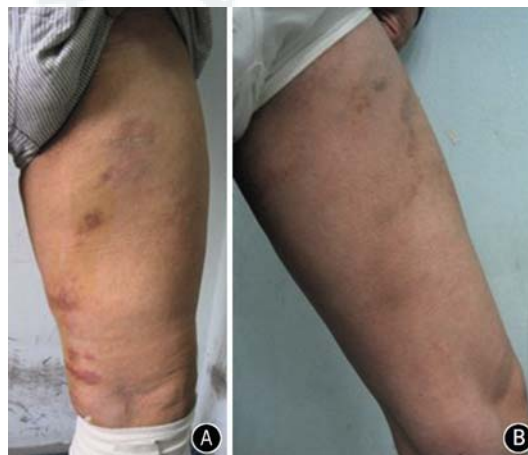### VAS

The results of pain score from all the 31 patients can also be seen in the chart; the score of one month postoperation was  $1.32 \pm 0.64$ , significantly different from that of one week preoperation ( $4.56 \pm 1.89$ ). So we considered that the patients recovered well and the operation did not increase magnificent complications, especially the pains. Paired *t*-test showed that *t* value was 8.048 (*P* < 0.05), showing significant differences.

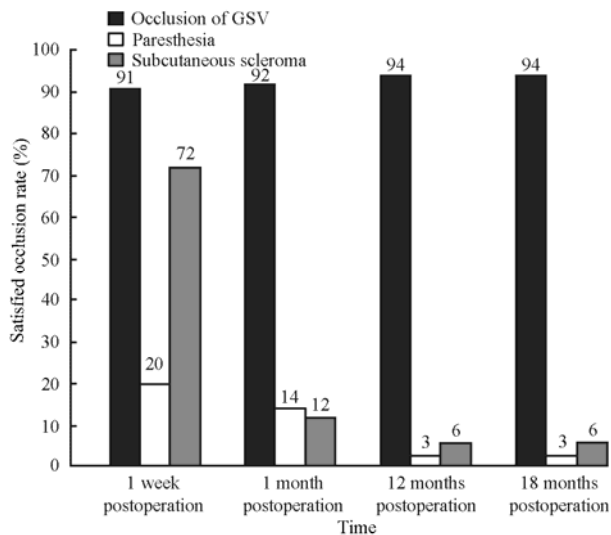
### Clinical assessments

The EVLA procedure was technically successful in all patients. None of the patients experienced any adverse event related to local anesthetic or adrenaline. All patients recovered well in the first postoperative week, and all except 2 (one had the history of keen-joint arthritis, the other had the history of medial meniscus damage) returned to their daily activities less than 7 days after the surgery, excluding physical activities such as running and swimming.

Hematoma in the GSV tunnel was observed in five patients (16.1%), with small ecchymosis (Figure 2). It was considered that these hemorrhagic areas were closely related to the punctured sites of tumescent infusion or laser ablation. Other side effects, such as induration and medial malleolus edema over the treated vein were quite common in the early post-ablation period, but self-limited during the first month following EVLA. No signs of neurologic lesion on the saphenous nerve were observed. No major complications, such as skin burns, deep vein thrombosis, or pulmonary embolism, occurred. The results of 1, 12, and 18 months after therapy brought to the satisfied occlusion rate of 92%, 94%, and 94%, respectively (Figure 3).



**Figure 2.** Ecchymosis on lower extremity after EVLA procedure. **A:** Three days postoperation. **B:** Seven days postoperation.



**Figure 3.** Occlusion and minor complication rates during follow-up periods.

Before the treatment, the mean GSV diameter, measured by CDU in an upright position at below the SFJ, was  $(6.52 \pm 2.07)$  mm. The mean length of GSV was  $(27.29 \pm 4.10)$  mm. In the immediate post-ablation period, successful occlusion was noted at 100%. Throughout the follow-up period, the mean GSV diameter decreased to  $(5.67 \pm 1.80)$ ,  $(5.72 \pm 1.00)$ , and  $(5.83 \pm 1.29)$  mm at 1, 12, and 18 months, respectively. Though there was no statistically significant difference between preoperation and postoperation GSV diameter ( $P > 0.05$ ), the showed a decreased trend of GSV diameter. What is more, the ultrasound imaging also displayed lack of compressibility and no endovascular spectrum signal for the treated GSV (Figure 4).

## DISCUSSION

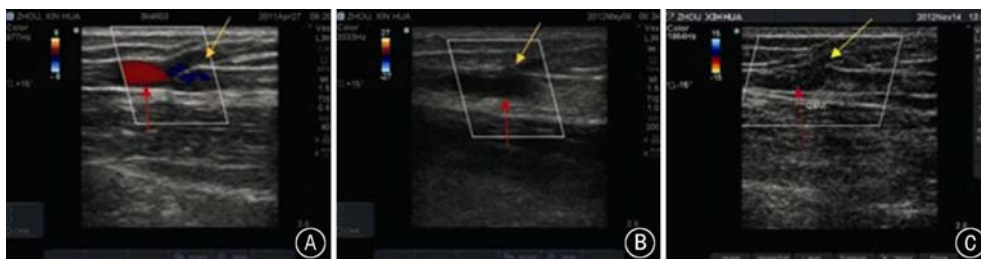Many studies have shown improvement of the surgical technique of insufficient GSV since the first description of GSV stripping in 1905,<sup>13,14</sup> but the optimal method of vein removal is still under debate. Many advocate a conventional approach using a classic acorn tip mounted on the stripper,<sup>15</sup> whereas others favor an invaginated procedure.<sup>16,17</sup> Hematoma formation is common in the stripping track after removal of the GSV and can cause pain and postoperative morbidity.

As the technical progression and the patients' requirement of safety and aesthetics, the treatment of varicose vein of lower extremities had changed from traditional open operation to minimal invasion. Since bone introduced

EVLA to the treatment of lower extremity varicose vein in 1998, it had been used widely and effectively in clinic because of the advantage of safety, convenience, minimal invasion, and short convalesce duration. In recent years, it has been reported that the effective rate of the occlusion of GSV ranged from 83.2% to 93.5% and 87.2% to 95.3% in 1 and 3-year-period, respectively, worldwide when EVLA was used to treat varicose GSV above articulation genus, while in China the effective rate ranged from 72.4% to 93.4% and 79.4% to 94.1% in 1- and 3-year-period, respectively.<sup>18</sup>

EVLA uses discontinuous or continuous laser of different wavelengths (810–1320 nm) through optical fiber into venous lumen to destroy the vascular wall and endothelial cells and make the vascular wall fibrosis heal and then closure permanently. Proebstle et al<sup>10</sup> elicited by experiments *in vivo* and *in vitro* that the penetration depth of the laser of 940 nm wavelength in the blood is only 0.3 mm. Then bubbles formatted on the top of the laser, which makes perverse indirect heat damage to the vascular wall and induces permanently closure of the lumen. Therefore, the laser energy, main determinant of success, is administered endovenously by continuous plus LPS fashion together with different degrees of LEED in our study. It shows successful early and midterm occlusion and low recanalization rates, which support the literature remarkably well.

The proper tumescent infusion technique is essential to ensure that the EVLA procedure is safe and less painful. We strongly believe that this technique can shorten recovery time, reduce complications, and improve occlusion rate. Perivenous fascial space containing the tumescent solution provides a margin of safety and prevents thermal injury to adjacent structures. In our observation under ultrasonography assessment during the ablation procedure, the tumescent infusion created a halo around the GSV to compress the vein and to minimize bleeding by mechanical effect and adrenaline's vasoconstrictor action; meanwhile, lidocaine was added to the solution not for anesthetic purposes but for analgesia in the post-operative period, as described by Nisar and colleagues.<sup>19</sup> The adrenaline concentration in the lidocaine solution is only 0.1 mg/20 ml, enough for vasoconstriction in reducing the bleeding, and its safety has previously been proven in studies on plastic surgery using tumescent anesthetic technique, with hematoma and hyperpigmentation rates close to 0%. This technique has contributed to the lack of skin burn or nerve damage in our patients. Our prospective research is the first report



**Figure 4.** Spectrum signal of the lumen of GSV (red arrow) and its branches (yellow arrow). **A:** Preoperative. **B:** Twelve months follow-up. **C:** Eighteen months follow-up.

using the refinement type of EVLA procedure with Ultrasound-Guide in China. It has shown a good clinical curative effect; furthermore, it is worth promoting by improving technique and instrument and performing long-period follow-up research with a wider sample.

EVLA is one of the most promising of the new techniques such as radiofrequency ablation and chemical ablation,<sup>2-5,20</sup> and is becoming an established treatment option for GSV and SSV incompetence. In the recent years, minimally invasive surgery has proved to be better than conservative treatment in symptomatic primary varicosis of GSV. By the confirmation of histological examination, the occlusion of lumen was caused by a series of pathological alteration. In sequence, there were ecclasis and hiatus of vein endothelial cells, breakage of middle elastic fiber, disorder of tissue structure, and secondary thrombosis in lumen, adhesion of lumen. Proebstle et al<sup>10</sup> considered that laser treatment had a destructive effect of thermal damage on vascular endothelial cells and intima, and then it caused the occlusion of vein. With success rates comparable to those of conventional surgery, EVLA has its own complications such as ecchymosis, postoperative pain, and paresthesias. Two main factors contributing to these complications may be perforation and unintentional vein wall contact, which cannot be avoided with any certainty because a bare-tip-fiber was used. So in several developed countries, some new instruments have been developed to prevent these complications in some Phase III clinical trials. The new instruments include tulip catheter, Elves radial fiber, and Jacket-tip-laser fiber.<sup>21</sup> The new developments could potentially reduce the risk of the complications, but accurate evaluation is needed. With the revolution of the instruments, EVLA maybe become the first-chosen method to treat varicose vein.

#### REFERENCES

- Fischer R, Linde N, Duff C, Jeanneret C, Chandler JG, Seeber P. Late recurrent saphenofemoral junction reflux after ligation and stripping of the greater saphenous vein. *J Vasc Surg* 2001; 34: 236-240.
- Luebke T, Brunkwall J. Systematic review and meta-analysis of endovenous radiofrequency obliteration, endovenous laser therapy, and foam sclerotherapy for primary varicosis. *J Cardiovasc Surg (Torino)* 2008; 49: 213-233.
- van den Bos R, Arends L, Kockaert M, Neumann M, Nijsten T. Endovenous therapies of lower extremity varicosities: a meta-analysis. *J Vasc Surg* 2009; 49: 230-239.
- Mundy L, Merlin TL, Fitrige RA, Hiller JE. Systematic review of endovenous laser treatment for varicose veins. *Br J Surg* 2005; 92: 1189-1194.
- Darwood RJ, Theivacumar N, Dellagrammaticas D, Mavor AI, Gough MJ. Randomized clinical trial comparing endovenous laser ablation with surgery for the treatment of primary great saphenous varicose veins. *Br J Surg* 2008; 95: 294-301.
- Pronk P, Gauw SA, Mooij MC, Gaastra MT, Lawson JA, van Goethem AR, et al. Randomised controlled trial comparing sapheno-femoral ligation and stripping of the great saphenous vein with endovenous laser ablation (980 nm) using local tumescent anaesthesia: one year results. *Eur J Vasc Endovasc Surg* 2010; 40: 649-656.
- Vuylsteke ME, Mordon SR. Endovenous laser ablation: a review of mechanisms of action. *Ann Vasc Surg* 2012; 26: 424-433.
- Lohr J, Kulwicki A. Radiofrequency ablation: evolution of a treatment. *Semin Vasc Surg* 2010; 23: 90-100.
- Johanson G, Rutherford RB. Varicose veins: patient selection and treatment. In: Rutherford RB, ed. *Vascular surgery*. 4th ed. Philadelphia: W.B. Saunders; 1995: 1825-1828.
- Proebstle TM, Moehler T, Herdemann S. Reduced recanalization rates of the great saphenous vein after endovenous laser treatment with increased energy dosing: definition of a threshold for the endovenous fluence equivalent. *J Vasc Surg* 2006; 44: 83483-83489.
- Zhang L, Zhang BG, Zhang JW, Zhang H. Immune function of erythrocytes in patients with chronic venous insufficiency of the lower extremities. *Chin Med J* 2007; 120: 2224-2228.
- Biemans AA, van der Velden SK, Bruijninx CM, Buth J, Nijsten T. Validation of the chronic venous insufficiency quality of life questionnaire in Dutch patients treated for varicose veins. *Eur J Vasc Endovasc Surg* 2011; 42: 246-253.
- Neser RA, Caffaro RA. Invagination stripping with ultrasound-guided perivenous tumescence: an original method of great saphenous vein stripping. *Dermatol Surg* 2011; 37: 349-352.
- Skykes TC, Brookes P, Hickey NC. A prospective randomized trial of tourniquet in varicose vein surgery. *Ann R Coll Surg Engl* 2000; 82: 280-282.
- Millien JP, Coget JM. Complications of superficial venous surgery of the legs: thigh haematomas and abscess. *Phlebologie* 1993; 46: 583-590.
- Keel D, Goldman MP. Tumescent anesthesia in ambulatory phlebectomy: addition of epinephrine. *Dermatol Surg* 1999; 25: 371-372.
- Scheltinga MR, Wijburg ER, Keulers BJ, de Kronn KE. Conventional versus invaginated stripping of the great saphenous vein: a randomized, double-blind, controlled clinical trial. *World J Surg* 2007; 31: 2236-2242.
- Min RJ, Khilnari N, Zimment SE. Endovenous laser treatment of saphenous Vein reflux: long-term results. *J Vasc Interv Radiol* 2003; 14: 991-996.
- Nisar A, Shabbir J, Tubassam MA, Shah AR, Khawaja N, Kavanagh EG, et al. Local anaesthetic flush reduces postoperative pain and haematoma formation after great saphenous vein stripping-a randomized controlled trial. *Eur J Vasc Endovasc Surg* 2006; 31: 325-331.
- Pannier F, Rabe E, Rits J, Kadiss A, Maurins U. Endovenous laser ablation of great saphenous veins using a 1470 nm diode laser and the radial fibre: follow-up after six months. *Phlebologie* 2011; 26: 35-39.
- Schwarz T, von Hodenberg E, Furtwängler C, Rastan A, Zeller T, Neumann FJ. Endovenous laser ablation of varicose veins with the 1470-nm diode laser. *J Vasc Surg* 2010; 51: 1474-1478.

(Received August 6, 2012)  
Edited by PAN Cheng