

Venous thromboembolism diagnosis: unresolved issues

Marc Righini¹; Grégoire Le Gal²; Henri Bounameaux¹

¹Division of Angiology and Hemostasis, Geneva University Hospital and Faculty of Medicine, Geneva, Switzerland; ²Ottawa Health Research Institute, Ottawa, Canada

Summary

Recent advances in the management of patients with suspected VTE have both improved diagnostic accuracy and made management algorithms safer, easier to use and well standardised. These diagnostic algorithms are mainly based on the assessment of clinical pretest probability, D-dimer measurement and imaging tests, mainly represented by compression ultrasound (CUS) for suspected DVT and computed tomography pulmonary angiography (CTPA) or lung ventilation-perfusion scan for pulmonary embolism. These diagnostic algorithms allow a safe and cost-effective diagnosis for most patients with suspected VTE. In this review, we focus on the challenge of diagnosing VTE in special patient populations, such as elderly patients, pregnant

women, or patients with a prior VTE. Some additional challenges are arising that might require adjustments to current diagnostic strategies, such as the reduced clinical suspicion threshold, resulting in a lower proportion of VTE among suspected patients; the overdiagnosis and overtreatment of VTE, especially regarding calf deep-vein thrombosis (DVT) and subsegmental pulmonary embolism (SSPE).

Keywords

Deep vein thrombosis, pulmonary embolism, D-dimer, age-adjusted D-dimer, compression ultrasonography, computed tomography pulmonary angiography

Correspondence to:

Marc Righini, MD
Division of Angiology and Hemostasis
Department of Medical Specialties
Geneva University Hospital and Faculty of Medicine
4, rue Gabrielle-Perret-Gentil
CH-1211 Geneva 14, Switzerland
Tel.: +41 22 372 92 94, Fax. +41 22 372 92 99
E-mail: Marc.Righini@hcuge.ch

Received: June 18, 2014

Accepted after minor revision: October 22, 2014

Epub ahead of print: December 11, 2014

<http://dx.doi.org/10.1160/TH14-06-0530>

Thromb Haemost 2015; 113: ■■■

Introduction

Venous thromboembolism (VTE) comprises of deep-vein thrombosis (DVT) and pulmonary embolism (PE). It is the third most common cardiovascular disease after acute coronary syndrome and stroke. Several major improvements have been made in the diagnostic algorithms: introduction of new diagnostic tests, simplification and reduced invasiveness of the diagnostic strategy.

Overview of current diagnostic strategies

Current diagnostic strategies rely on the sequential use of diagnostic tests stratified on clinical pre-test probability assessment (1, 2), which can be assessed either empirically (“Gestalt”) or with clinical prediction rules (CPR). The use of CPR allows a standardised, accurate and transferable estimate of the clinical probability (3–5). Main available CPR for PE are summarised in ►Table 1. The Wells rule and the Geneva rules under their various versions are the most widely validated rules for PE (3). A recent direct prospective comparison of the four rules (Wells rule, revised Geneva score, simplified Wells rule, and simplified revised Geneva score) showed similar diagnostic performances (4). D-dimer measurement is a simple non-invasive blood test that allows to safely rule out VTE when below a certain cut-off ($\leq 500 \mu\text{g/l}$ for most tests) in patients with a non-high or an unlikely clinical probability (6–8).

Patients with a D-dimer above the cut-off or a high/likely clinical probability should undergo imaging tests.

In patients with suspected DVT, venous ultrasound is the option of choice. In patients with suspected PE, computed tomography pulmonary angiography (CTPA) and ventilation-perfusion lung scan (V/Q scan) are the two recommended imaging tests. An example of validated diagnostic algorithm for both DVT and PE is displayed in ►Figure 1.

Unresolved issues in VTE diagnosis

Elderly patients

Elderly patients have the highest risk of VTE with an incidence above 1%/year (9). VTE diagnosis is particularly challenging in the elderly, and consists of answering the following question: “should I suspect VTE in this patient?” Aging is associated with an increasing prevalence of cardiac or pulmonary comorbidities, and because the clinical symptoms and signs of PE are not specific to PE, the initial assessment of patients can be really puzzling for the clinician. Whereas typical symptoms and signs suggestive of PE are found in the majority of patients with PE who do not have pre-existing cardiac or pulmonary diseases (10), this is not the case in elderly patients. In small retrospective series of elderly patients with confirmed PE, clinical presentation is shown to differ from

that observed in younger patients, syncope being more often present whereas pleuritic chest pain is consistently less frequently reported than in younger patients (11–13).

Because of increasing availability of imaging techniques, especially CT pulmonary angiogram (CTPA), it can be tempting to systematically add PE to a list of differential diagnoses without refining clinical assessment (14). Such a strategy is obviously not acceptable, not only in terms of available resources but also because of the potential nephrotoxicity of the iodine contrast dye in a population with a high prevalence of renal insufficiency (15) and hence at higher risk for contrast-induced nephropathy (16). Balancing undersuspicion and oversuspicion of PE is therefore particularly challenging in the elderly.

In addition to the high frequency of alternative diagnoses, another difficulty in diagnosing VTE in this population is the modified performances of usual diagnostic tests. In particular, D-dimer levels increase with age and as a result the diagnosis of PE is ruled out on the basis of a negative D-dimer in only 5% of patients 80 years of age and older, as compared with >50% of patients aged <50 years (17).

Several attempts to improve the performance of D-dimer in elderly patients have been pursued. For example, an age-adjusted cut-off for patients with suspected PE was derived: the optimal cut-off value (in mg/l) appears to be equal to patient's age (in years) by 10, in patients over 50 years with a non-high pretest clinical probability of VTE (18). Very recently, a large prospec-

Table 1 : Clinical prediction rules for PE.

Geneva (58)	Points	Revised Geneva (59)	Points	Wells (60)	Points	Miniati (61, 62)	Coefficient
Recent surgery	3.0	Age >65 years old	1.0	Clinical signs of DVT	3.0	Male sex	0.81
Previous DVT or PE	2.0						
60–79 years old	1.0	Previous history of PE or DVT	3.0	Recent surgery or immobilisation	1.5	Age	
≥80 years old	2.0	Surgery or fracture within 1 month	2.0	Heart rate > 100 bpm	1.5	63–72 years old	0.59
Heart rate > 100 beats per minutes	1.0	Active malignancy	2.0	Previous history of PE or DVT	1.5	≥ 73 years old	0.92
<i>Chest radiography:</i>		<i>Heart rate (bpm)</i>		Haemoptysis	1.0	Preexisting cardiovascular disease	-0.56
Atelectasis	1.0	75–94	3.0	Malignancy	1.0	Preexisting pulmonary disease	-0.97
Elevated hemidiaphragm	1.0	≥ 95	5.0	Alternative diagnosis less likely than PE	3.0	History of thrombophlebitis	0.69
<i>PaO₂:</i>		Pain on leg deep-vein palpation	4.0			Dyspnea (sudden onset)	1.29
< 49 mm Hg (6.5 kPa)	4.0	Unilateral leg pain	3.0			Chest pain	0.64
49–59 mm Hg (6.5–7.99 kPa)	3.0	Haemoptysis	2.0			Haemoptysis	0.89
60–71 mm Hg (8–9.49 kPa)	2.0					Fever > 38°	-1.17
72–82 mmHg (9.5–10.99 kPa)	1.0					ECG signs of acute right ventricular overload	1.53
<i>PaCO₂:</i>				3 levels		Chest radiograph	
< 36 mmHg (4.8 kPa)	2.0			Low	< 2	Oligoemia	3.86
36–38.9 mmHg (4.8–5.2 kPa)	1.0			Intermediate	2–6	Amputation of the hilar artery	3.92
				High	> 6	Consolidation (infarction)	3.55
Low	0–4	Low	0–3			Consolidation (no infarction)	-1.23
Intermediate	5–8	Intermediate	4–10			Pulmonary oedema	-2.83
	≥ 9	High	≥ 11	2 levels		Constant	-3.26
				PE unlikely	≤ 4		
				PE likely	> 4		

Table 1 : Continued

Charlotte Rule (63)	Points	Simp. Rev.Geneva (64)	Points	Simp. Wells (65)	Points	Pretest probability (%)=1/[1+exp(-sum)]	
>50 years old		Age >65 years old	1.0	Clinical signs of DVT	1.0		
Heart rate > systolic blood pressure		Previous history of PE or DVT	1.0	Recent surgery or immobilisation	1.0	4 levels	
Unexplained hypoxaemia (O ₂ <95 %)		Surgery or fracture within 1 month	1.0	Heart rate > 100 beats per minutes	1.0	Low	≤ 10 %
Recent surgery (previous 4 weeks)		Active malignancy	1.0	Previous history of PE or DVT	1.0	Intermediate	10–50 %
Haemoptysis		Heart rate (bpm)		Haemoptysis	1.0	Moderately High	50–90 %
Unilateral leg swelling		75–94	1.0	Malignancy	1.0	High	> 90 %
		≥ 95	1.0	Alternative diagnosis less likely than PE	1.0		
Any of the previous present	Unsafe	Pain on leg deep-vein palpation	1.0				
All of the previous absent	Safe	Unilateral leg pain	1.0			3 levels	
		Haemoptysis	1.0			Low	≤ 10 %
						Intermediate	10–90
	Low	0–1	Unlikely	≤ 1	High	> 90 %	
	Intermediate	2–4	Likely	> 1			
		High	≥ 5				

DVT, deep-vein thrombosis; PE, pulmonary embolism; Simp: simplified.

tive diagnostic management outcome study was completed, in which all non-high clinical probability patients with D-dimer levels below their age-adjusted cut-off were left untreated with no further diagnostic testing (19). In this study, using the age-adapted cut-off increased five-fold the number of elderly patients in whom PE could be ruled out on the basis of D-dimer testing without compromising safety, and decreased the need for imaging thoracic tests. Importantly, while retrospective validation of the adjusted D-dimer cut-off is available for both PE and DVT (20), a prospective management outcome study is lacking for DVT.

Compression ultrasonography (CUS) might also have some interest in elderly patients in whom CTPA is contra-indicated. Indeed, in a patient with suspected PE, the presence of a *proximal* DVT is highly predictive of PE (positive likelihood ratio of 42) allowing to rule in the diagnosis of PE without further thoracic imaging (21). Interestingly, data from two large prospective management outcome studies enrolling more than 1,000 consecutive patients with suspected PE showed a higher yield of CUS in elderly patients compared to younger patients. Proximal DVT was found in 7% of patients <40 years but in 25% of those >80 years, corresponding to a NNT of only 4 in the older group to rule in one PE without further imaging (17). It thus seems useful to perform CUS as the initial imaging test in elderly patients with severe renal failure. However, an unfortunately frequent mistake made by clinicians is to stop investigations after a normal CUS. This is of course

unacceptable as the absence of proximal DVT does not rule out PE, and further thoracic imaging with V/Q scan is necessary in this setting, unless an alternative diagnosis has become obvious or PE is no longer suspected.

The main limitation of V/Q scan is an important proportion of non-diagnostic results, which increases with age (from 32% in patients <40 years to 58% in those >80 years) (17). V/Q scan results thus need to be interpreted in conjunction with clinical probability, D-dimer and CUS, the latter sometimes being repeated at a week's interval in order to safely exclude PE (22). For example, in a study by Anderson et al., whenever there was an instance of an inconclusive (i.e. low or intermediate probability) ventilation perfusion lung scan, a CUS was performed. If positive, the diagnosis of PE was confirmed. If negative in a patient with an unlikely clinical probability or a negative D-dimer test, PE was ruled out. If negative in a patient with a likely clinical probability or a positive D-dimer test, a serial CUS was performed (23).

Pregnant women

The risk of VTE is significantly increased during pregnancy, and VTE remains one of the main causes of maternal mortality in developed countries. The diagnosis of VTE remains a challenge in pregnant women: symptoms such as shortness of breath or leg swelling are common during normal pregnancy and the symptoms and signs of VTE are modified during pregnancy.

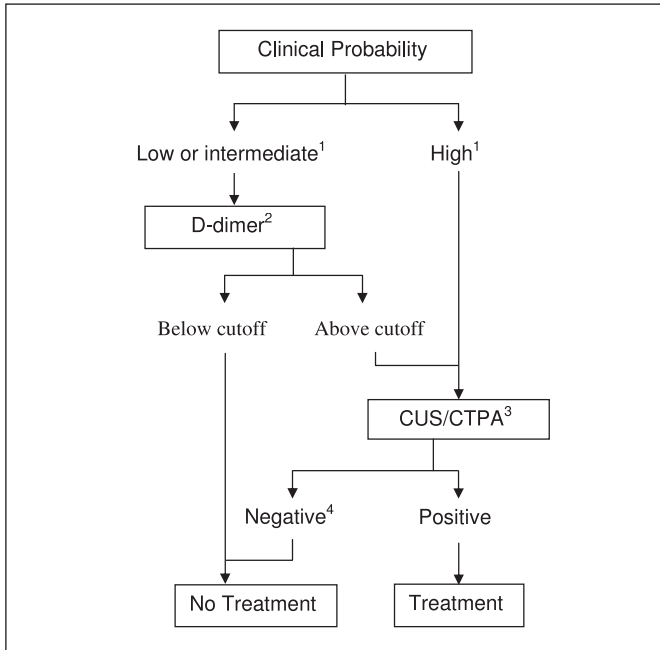


Figure 1: Diagnostic strategy of venous thromboembolic disease (adapted from [8] and [19]). ¹If using a highly sensitive D-dimer assay; if a less sensitive assay is used, a negative test result rules out DVT or PE only in patients with low (or unlikely) clinical probability. ²The use of an age-adjusted D-dimer has been prospectively validated in patients with suspected PE. ³CUS (lower limb serial proximal or single whole-leg venous compression ultrasonography) in case of suspected DVT; CTPA (computed tomography pulmonary angiography) in case of suspected PE. ⁴In case of negative CUS or CTPA in high clinical probability patients, additional imaging, e.g. venography (suspected DVT) or lung ventilation/perfusion scintigraphy or pulmonary angiography (suspected PE) might be considered.

Recently, Chan et al. proposed a clinical prediction rule for suspected DVT: the LEft rule (24). It combines three variables: symptoms in the left leg (“L”), calf circumference difference of 2 cm (“E” for edema) and first trimester presentation (“Ft”). An external retrospective validation suggested that the “LEft” rule accurately

Table 2: Diagnostic performances of the “LEft” rule (adapted from [25]).

	n (%)	Proportion of DVT n (%)	P-value
LEft score (points)			
0	46 (29.3)	0 (0.0)	<0.001
1	83 (52.9)	4 (4.8)	
2	24 (15.3)	7 (29.2)	
3	4 (2.5)	2 (50.0)	
LEft score			
0	46 (29.3)	0 (0.0)	0.002
≥1	111 (70.7)	13 (11.7)	

discriminated pregnant women with suspected DVT (25). Indeed, the proportion of DVT in patients with 0, 1, 2 and 3 points was of 0/46 (0.0%), 4/83 (4.8%), 7/24 (29.2%) and 2/4 (50%), respectively (► Table 2). Moreover, the area under the receiver-operating characteristics (ROC) curve was similar to that of other rules often used in VTE disease: 0.84 (95% confidence interval [CI]: 0.73–0.94). However, it remains to be prospectively validated and its role in the diagnostic strategy is not established. A clinical CPR is still lacking for suspected PE in pregnant women.

D-dimer levels increase during pregnancy, reducing the likelihood of a negative result. Chan et al. proposed adapted D-dimer thresholds for many D-dimer tests (26). However, there is no data arising from a prospective outcome study to support the safety of excluding VTE in pregnant women using these cut-offs. As a result, most women with suspected VTE undergo imaging tests, which turns out to be negative much more frequently than in non-pregnant patients (27, 28).

The performance of CUS for DVT diagnosis could be limited due to a higher proportion of isolated iliac DVT and to modified conditions of observation. Two outcome management studies support the use of either a single whole-leg venous ultrasound or a serial proximal ultrasound to rule out DVT in pregnant women, with the limitation of small sample sizes (27, 29). Importantly, a Doppler examination of the iliac veins was part of the ultrasound protocol in the two studies. A diagnostic algorithm is proposed in ► Figure 2. However, more data is needed, including a prospective management study in which patients’ management would be based on the results of the LEft clinical decision rule in combination with D-dimer and CUS in this setting. Such a trial is actively recruiting patients (NCT01708239).

In pregnant women with suspected PE, there is a debate in the choice of the imaging thoracic test, mainly around the risk associated to fetus and mother irradiation. Some studies suggested that the level of radiation to the fetus is lower with CTPA than with V/Q scan (30). On the other hand, some studies warned about the increased risk of breast cancer in women exposed to CTPA (31), which could be even higher during pregnancy.

However, these risks are clearly outweighed by the risks of PE misdiagnosis. In terms of radiation exposure, all radiological tests fall well below the limit considered as dangerous for the fetus. The key message is that all pregnant women with suspected PE should undergo a complete diagnostic work-up (32, 33). A diagnostic algorithm is proposed in ► Figure 3. However, formal validation of a diagnostic strategy for PE in pregnant women is still lacking.

Patients with prior VTE

Patients with prior VTE often have persistently elevated D-dimer levels. As such, in case of suspected recurrent VTE, a lower proportion of them will benefit from non-invasive testing: the proportion of patients in whom PE was ruled out on the basis of a negative D-dimer were 16% and 33% in patients with and without a history of previous VTE, respectively (34). Patients with prior VTE have modified symptoms and signs because of residual mani-

festations of previous episodes (chronic leg pain and swelling after DVT, persistent shortness of breath after PE) (35, 36). Finally, the interpretation of imaging tests is difficult because of the presence of frequent residual thrombi that are sometimes difficult to distinguish from an acute recurrent thrombus, thereby resulting in overdiagnosis (37). Some diagnostic criteria for recurrent VTE have been proposed based on the comparison of imaging result with previous imaging: involvement of a new venous segment, increase by >4 mm in the diameter of a previously visualised thrombus on venous ultrasound, or apparition of a new perfusion defect on V/Q scan (38–40). However, this strategy requires the realisation of a complete baseline imaging and is only useful if 1) standardised measurements are reported and 2) these images are available at the time and place of the suspected recurrent event and 3) if we dismiss possible asymptomatic events.

The performance of CUS could also be optimised. Some ultrasonographic features are often seen in patients with chronic thrombi: thickened vein walls, valvular damage and reflux, developed collateral veins. Furthermore, the vein is typically not as enlarged as what is seen in acute DVT. Chronic thrombi are often hyperechogenic and/or non-occlusive, the rate of recanalisation being highly variable over time and from one patient to another (39). However, whether or not the diagnosis of acute recurrent DVT can be safely ruled out on the basis of the presence of one of these findings has not been evaluated.

Another approach is to develop new diagnostic imaging tests that could differentiate acute and chronic thrombi. Dedicated

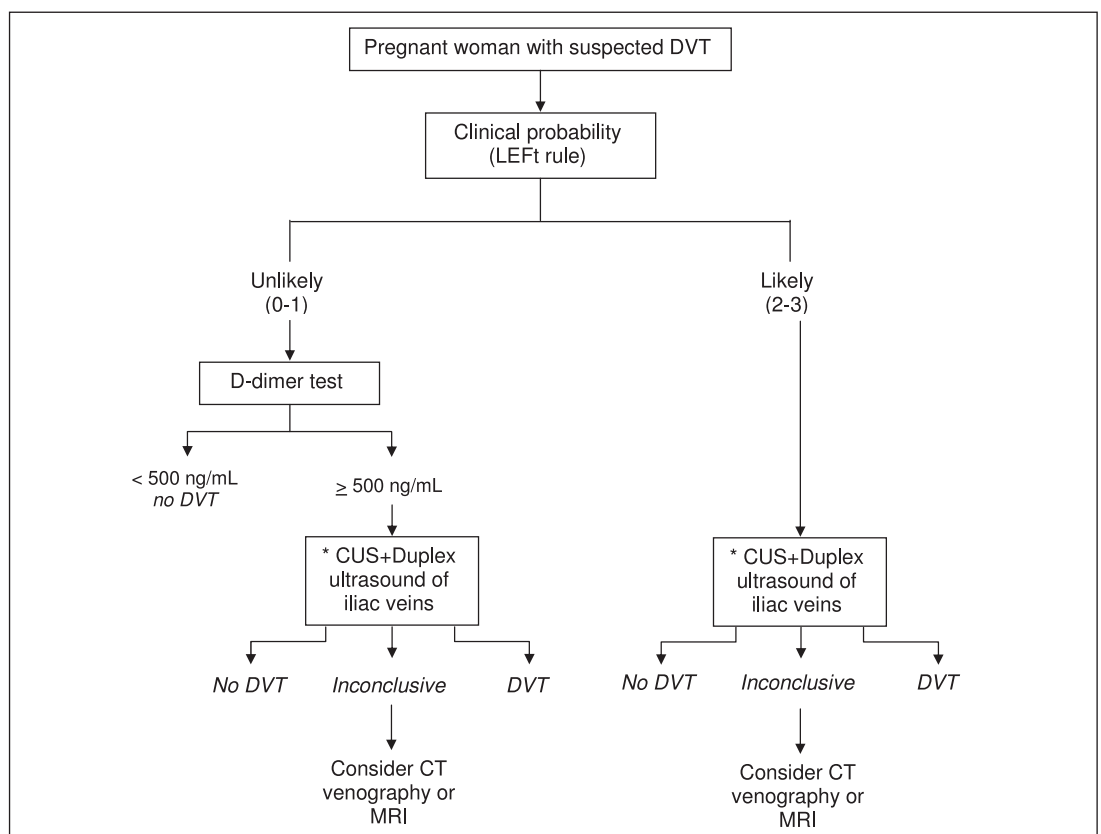
magnetic resonance imaging T1 sequences could provide accurate diagnosis of acute vs chronic DVT (41). In a recent study, magnetic resonance 'direct thrombus imaging' (MRDTI) technique was able to differentiate acute and chronic thrombi: the sensitivity, and specificity for acute recurrent DVT were 95% (95% CI 83 to 99%) and 100% (95% CI 92 to 100%), respectively, with an excellent inter-observer agreement (kappa 0.98) (42). However, broad clinical implementation might be limited by the high technical demand and long image acquisition times of MRDTI (43). Some specific radiotracers such as ^{99m}Tc-labelled anti-D-dimer antibodies or ^{99m}Tc-recombinant tissue plasminogen activator are also under development (43).

Isolated symptomatic subsegmental PE and calf DVT

Attention to subsegmental pulmonary embolism (SSPE) has increased with the ability of CTPA to show such small PE, not to mention ongoing debate about unsuspected PE, which will not be discussed herein. The exact prevalence of SSPE in patients with suspected PE varies between 0.4 and 18% according to literature (44). The prevalence is probably dependent from the number of detectors. A systematic review of diagnostic studies in patients with suspected PE found isolated subsegmental PE in 4.7% of patients with PE diagnosed by single-detector CT and in 9.4% of patients with PE diagnosed by multi-detector CTPA (45).

One of the main problems is that the reading of modern multi-row CTPA is complicated and time-consuming. Radiologists are

Figure 2: Proposed diagnostic algorithm for suspected DVT in pregnant women.*
Either single whole-leg or serial proximal CUS. CT: computed tomography; DVT: deep-vein thrombosis; MRI: magnetic resonance imaging. Please note that this proposed strategy has not been validated.



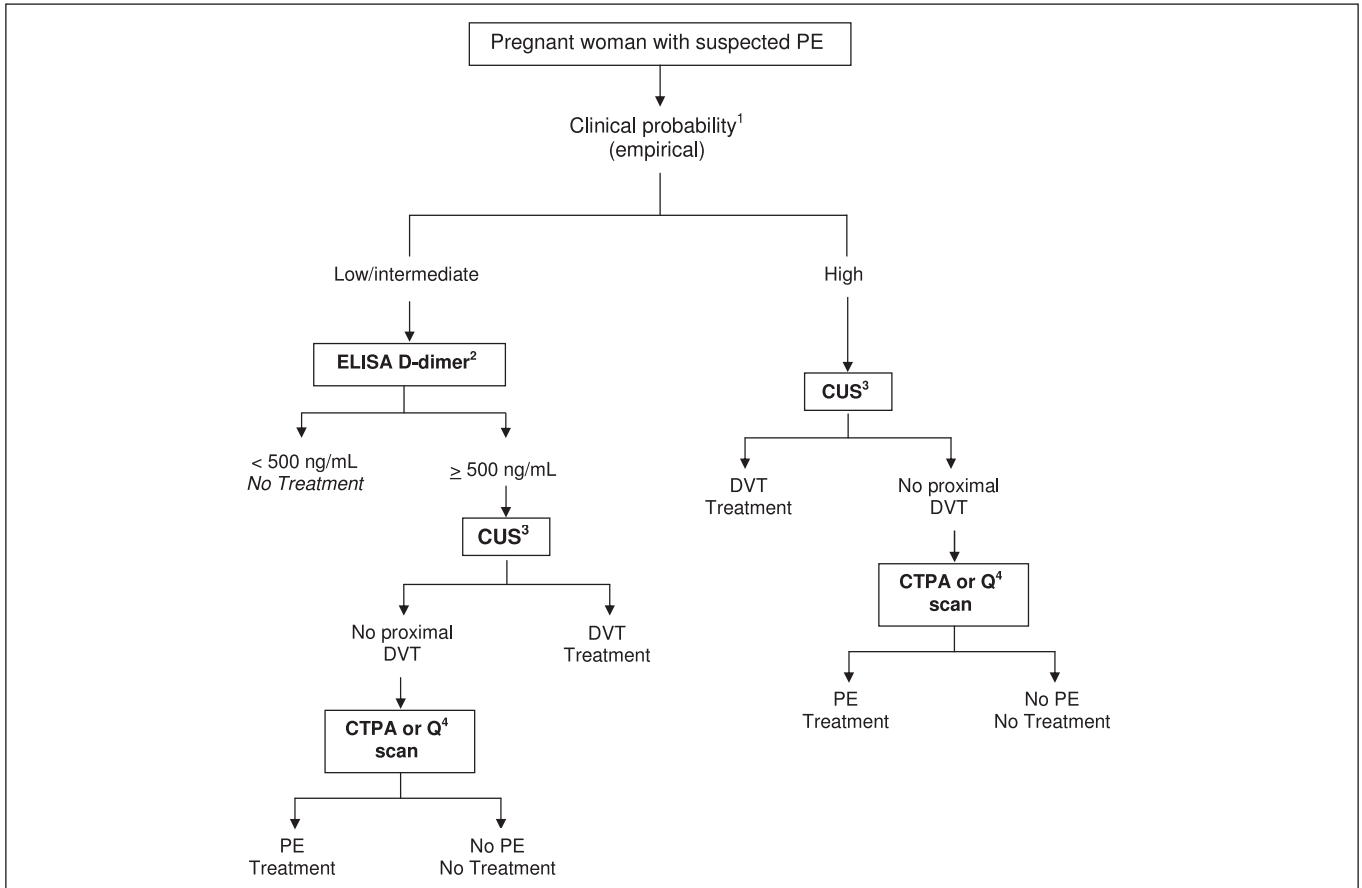


Figure 3: Proposed diagnostic algorithm for suspected PE in pregnant women. ¹Assessment of clinical probability is empirical as no usual clinical prediction rule as the Wells score or the Geneva rule has been validated in pregnant women. ²A D-dimer level below the usual cut-off of 500 ng/ml should allow to rule out PE in pregnant women, even if this has never been formally validated in a prospective management outcome study. ³Although the rate of positive finding is lower in patients without leg symp-

toms, the presence of a proximal DVT in a patient with suspected PE allows to rule in PE diagnosis and avoids the need for a radiating test. ⁴While Q scan is the most often used imaging test to rule out PE in pregnant women, formal validation is poor. Data regarding ventilation perfusion lung scan are also scarce. CTPA is increasingly used but is associated with the concerns of maternal radiation. Please note that this proposed strategy has not been validated.

often faced with small images which makes interpretation difficult. Of note, in the PIOPED II trial, the positive predictive value of CTPA (when compared to a composite standard reference) was of 98% for central PE but was only of 25% for subsegmental PE (46). Therefore, the most puzzling question might well be: "is this image truly a subsegmental PE?"

In a time-trend analysis of the incidence and mortality of PE in the United States, authors concluded that the introduction of CTPA was associated with changes consistent with overdiagnosis: rising incidence but minimal change in mortality and lower case-fatality (47). Even when images with thin-collimation multidetector CT are compelling, the clinical relevance and management of patients with symptomatic SSPE is controversial (48, 49). Indeed, only few investigations have evaluated the outcome of untreated patients with symptomatic isolated subsegmental PE. In a recent systematic review and meta-analysis, the three-month thromboembolic risk in patients with suspected PE who were left untreated based on a diagnostic algorithm including a negative single-detector CTPA was 0.9% (95% CI: 0.4–1.4). It was of 1.1%

(95% CI: 0.7–1.4) in patients left untreated after a multi-detector CTPA. This might suggest that the use of multi-detectors CT increases the rate of SSPE detection, but without resulting in a decreased three-month thromboembolic risk (45). A recent review of the literature including four diagnostic studies reported a favourable outcome in 60 patients left untreated after the diagnosis of SSPE without associated DVT (50).

In a statement from the Fleischner Society on the management of suspected acute PE, it is suggested that the clinical relevance of small peripheral PE and the need to give anticoagulant treatment in such patients is a matter to debate (51). They also suggested that in patients with small PE and no DVT, the risks associated with anticoagulant treatment might outweigh the benefits. An ongoing study, in which patients with symptomatic SSPE, no DVT and no cancer are left untreated and carefully followed for a three-month period, will add useful data to this complex topic (NCT01455818).

Isolated calf DVT represents a similar problem, even if more data are available. The standard diagnostic approach of suspected DVT is serial lower limb CUS of proximal veins. Although it only

assesses the proximal veins, withholding anticoagulant treatment in patients with a negative CUS on day one and after one week has been proved safe. In particular, studies evaluating CUS limited to the proximal veins showed a good safety profile with a pooled estimate of the three-month thromboembolic rate of 0.6% (95% CI: 0.4–0.9%) in patients not given anticoagulant therapy (52). However, performing two lower limbs CUS is cumbersome and expensive. Recently, studies using a unique whole-leg (proximal and distal) CUS showed a similar pooled estimate of the three-month thromboembolic rate (0.3%, 95% CI: 0.1–0.6%) but distal DVTs accounted for as many as 50% of all diagnosed DVTs in those series (52). In a recent prospective randomised multicentre trial, serial two-point CUS with D-dimer testing was compared with single whole-leg CUS strategy in more than 2,000 outpatients with a clinical suspicion of DVT (53). Patients with a normal two-point CUS underwent qualitative D-dimer testing (SimpliRED®, Agen Biomedical, Acacia Ridge, QLD, Australia). Patients with negative D-dimer were spared further investigations and not treated with anticoagulants. Patient with abnormal D-dimer levels underwent repeat CUS at one week. Both strategies reported similar three-month rate of VTE: 0.9% (95% CI 0.3–1.8%) for the serial two-point CUS arm vs 1.2% (95% CI 0.5–2.2%) for the whole-leg strategy. Safety of both strategies was therefore similar. Nevertheless, it should be noted that 23% (65/278) of patients in the whole-leg CUS group were treated with anticoagulant for a distal DVT, without decreasing the three-month thromboembolic risk (53). Admittedly, performing calf CUS may be useful in diagnosing other conditions such as popliteal cyst, haematoma or muscle rupture. Also, requesting to perform a CUS limited to the popliteal site in presence of calf pain may not be approved by the patient. A randomised double-blind trial comparing placebo and elastic compression to therapeutic anticoagulant treatment and elastic compression in patients with symptomatic calf DVT should add useful data to improve the management of isolated calf DVT (NCT00421538).

Future insights

New diagnostic tools

Planar lung ventilation-perfusion (V/Q) scan has been the first imaging test developed to replace pulmonary angiography, the gold-standard test for PE (54). One of its main drawbacks is a high proportion of non-conclusive tests, therefore requiring further imaging. Recently, nuclear medicine physicians developed the use of SPECT (Single Photon Emission Computed Tomography) V/Q scan. This imaging modality is very similar to conventional V/Q but enables tomographic imaging, which allows better contrast resolution and limits the overlapping of perfusion defects by other structures. Another advantage would be to limit the use of CTPA, as increasing use raises concerns about excessive exposure of the population to radiations. Also, the use of CTPA appears to be associated with an overdiagnosis of PE (see above, section on subsegmental PE). In a trial comparing a diagnostic strategy based on CTPA with a strategy based on planar V/Q scan, the two strategies

had similar safety, but the use of CTPA was associated with a 30% higher proportion of confirmed PE (19% in the CTPA arm, vs 14% in the V/Q arm) (23).

Accuracy studies on the SPECT V/Q have shown appealing results (55). However, before the SPECT V/Q can be implemented in clinical practice, a management study in which clinical decisions would be made on the basis of this test remains to be conducted.

Another potential diagnostic tool is contrast enhanced or not enhanced magnetic resonance imaging. However, studies published so far reported a high proportion of technically inadequate tests and a limited overall sensitivity (56, 57). This modality could be useful in patients with contraindications to CTPA (contrast-induced nephropathy, allergy) or in pregnant women. An ongoing prospective management study is currently evaluating the diagnostic performances of contrast-enhanced MRI and lower-limb CUS (NCT02059551).

Conclusion

During the last two decades, the improvement of diagnostic strategies almost completely eliminated the need for invasive diagnostic testing (phlebography and pulmonary angiography). Current algorithms are fairly simple, easy to use and cost-effective. The diagnosis of VTE in special patient populations such as elderly patients, pregnant women, suspected VTE recurrence remains challenging. There are also some additional challenges arising that might require adjustments to current diagnostic strategies such as the reduced clinical suspicion threshold resulting in a lower proportion of VTE in suspected patients; the problem of overdiagnosis and overtreatment especially regarding calf DVT and SSPE. A better risk stratification or the use of new diagnostic modalities might help resolving these issues.

Conflicts of interest

None declared.

References

1. Perrier A, Roy PM, Sanchez O, et al. Multidetector-row computed tomography in suspected pulmonary embolism. *N Engl J Med* 2005; 352: 1760–1768.
2. van Belle A, Buller HR, Huisman MV, et al. Effectiveness of managing suspected pulmonary embolism using an algorithm combining clinical probability, D-dimer testing, and computed tomography. *J Am Med Assoc* 2006; 295: 172–179.
3. Ceriani E, Combescurie C, Le Gal G, et al. Clinical prediction rules for pulmonary embolism: a systematic review and meta-analysis. *J Thromb Haemost* 2010; 8: 957–970.
4. Douma RA, Mos IC, Erkens PM, et al. Performance of 4 clinical decision rules in the diagnostic management of acute pulmonary embolism: a prospective cohort study. *Ann Intern Med* 2011; 154: 709–718.
5. Wells PS, Anderson DR, Bormanis J, et al. Value of assessment of pretest probability of deep-vein thrombosis in clinical management. *The Lancet* 1997; 350: 1795–1798.
6. Carrier M, Righini M, Djurabi RK, et al. VIDAS D-dimer in combination with clinical pre-test probability to rule out pulmonary embolism. A systematic review of management outcome studies. *Thromb Haemost* 2009; 101: 886–892.

7. Di Nisio M, Squizzato A, Rutjes AW, et al. Diagnostic accuracy of D-dimer test for exclusion of venous thromboembolism: a systematic review. *J Thromb Haemost* 2007; 5: 296–304.
8. Righini M, Perrier A, De Moerloose P, et al. D-Dimer for venous thromboembolism diagnosis: 20 years later. *J Thromb Haemost* 2008; 6: 1059–1071.
9. Oger E. Incidence of venous thromboembolism: a community-based study in Western France. EPI-GETBO Study Group. Groupe d'Etude de la Thrombose de Bretagne Occidentale. *Thromb Haemost* 2000; 83: 657–660.
10. Stein PD, Gottschalk A, Saltzman HA, et al. Diagnosis of acute pulmonary embolism in the elderly. *J Am Coll Cardiol* 1991; 18: 1452–1457.
11. Timmons S, Kingston M, Hussain M, et al. Pulmonary embolism: differences in presentation between older and younger patients. *Age Ageing* 2003; 32: 601–605.
12. Kokturk N, Oguzulgen IK, Demir N, et al. Differences in clinical presentation of pulmonary embolism in older vs younger patients. *Circ J* 2005; 69: 981–986.
13. Robert-Ebadi H, Le Gal G, Carrier M, et al. Differences in clinical presentation of pulmonary embolism in women and men. *J Thromb Haemost* 2010; 8: 693–698.
14. Le Gal G, Bounameaux H. Diagnosing pulmonary embolism: running after the decreasing prevalence of cases among suspected patients. *J Thromb Haemost* 2004; 2: 1244–1246.
15. Meguid El Nahas A, Bello AK. Chronic kidney disease: the global challenge. *Lancet* 2005; 365: 331–340.
16. Mehran R, Aymong ED, Nikolsky E, et al. A simple risk score for prediction of contrast-induced nephropathy after percutaneous coronary intervention: development and initial validation. *J Am Coll Cardiol* 2004; 44: 1393–1399.
17. Righini M, Goehring C, Bounameaux H, et al. Effects of age on the performance of common diagnostic tests for pulmonary embolism. *Am J Med* 2000; 109: 357–361.
18. Douma RA, le Gal G, Sohne M, et al. Potential of an age adjusted D-dimer cut-off value to improve the exclusion of pulmonary embolism in older patients: a retrospective analysis of three large cohorts. *Br Med J* 2010; 340: c1475.
19. Righini M, Van Es J, Den Exter PL, et al. Age-adjusted D-dimer cut-off levels to rule out pulmonary embolism: the ADJUST-PE study. *J Am Med Assoc* 2014; 311: 1117–1124.
20. Douma RA, Tan M, Schutgens R, et al. Age-dependent D-dimer cut-off value increases the number of older patients in whom deep vein thrombosis can be safely excluded. *Haematologica* 2012; 97: 1507–1513.
21. Le Gal G, Righini M, Sanchez O, et al. A positive compression ultrasonography of the lower limb veins is highly predictive of pulmonary embolism on computed tomography in suspected patients. *Thromb Haemost* 2006; 95: 963–966.
22. Wells PS, Anderson DR, Rodger M, et al. Excluding pulmonary embolism at the bedside without diagnostic imaging: management of patients with suspected pulmonary embolism presenting to the emergency department by using a simple clinical model and d-dimer. *Ann Intern Med* 2001; 135: 98–107.
23. Anderson DR, Kahn SR, Rodger MA, et al. Computed tomographic pulmonary angiography vs ventilation-perfusion lung scanning in patients with suspected pulmonary embolism: a randomized controlled trial. *J Am Med Assoc* 2007; 298: 2743–2753.
24. Chan WS, Lee A, Spencer FA, et al. Predicting deep venous thrombosis in pregnancy: out in „LEFT“ field? *Ann Intern Med* 2009; 151: 85–92.
25. Righini M, Jobic C, Boehlen F, et al. Predicting deep venous thrombosis in pregnancy: external validation of the LEFT clinical prediction rule. *Haematologica* 2013; 98: 545–548.
26. Chan WS, Lee A, Spencer FA, et al. D-dimer testing in pregnant patients: towards determining the next 'level' in the diagnosis of deep vein thrombosis. *J Thromb Haemost* 2010; 8: 1004–1011.
27. Le Gal G, Kercret G, Ben Yahmed K, et al. Diagnostic value of single complete compression ultrasonography in pregnant and postpartum women with suspected deep vein thrombosis: prospective study. *Br Med J* 2012; 344: e2635.
28. Chan WS, Ray JG, Murray S, et al. Suspected pulmonary embolism in pregnancy: clinical presentation, results of lung scanning, and subsequent maternal and pediatric outcomes. *Arch Intern Med* 2002; 162: 1170–1175.
29. Chan WS, Chunilal S, Lee A, et al. A red blood cell agglutination D-dimer test to exclude deep venous thrombosis in pregnancy. *Ann Intern Med* 2007; 147: 165–170.
30. Nijkeuter M, Geleijns J, de Roos A, et al. Diagnosing pulmonary embolism in pregnancy: rationalizing fetal radiation exposure in radiological procedures. *J Thromb Haemost* 2004; 2: 1857–1858.
31. Einstein AJ, Henzlova MJ, Rajagopalan S. Estimating risk of cancer associated with radiation exposure from 64-slice computed tomography coronary angiography. *J Am Med Assoc* 2007; 298: 317–323.
32. Roy P-M, Meyer G, Vielle B, et al. Appropriateness of Diagnostic Management and Outcomes of Suspected Pulmonary Embolism. *Ann Intern Med* 2006; 144: 157–164.
33. Konstantinides SV, Torbicki A, Agnelli G, et al. 2014 ESC Guidelines on the diagnosis and management of acute pulmonary embolism: The Task Force for the Diagnosis and Management of Acute Pulmonary Embolism of the European Society of Cardiology (ESC) Endorsed by the European Respiratory Society (ERS). *Eur Heart J* 2014; Epub ahead of print.
34. Le Gal G, Righini M, Roy PM, et al. Value of D-dimer testing for the exclusion of pulmonary embolism in patients with previous venous thromboembolism. *Arch Intern Med* 2006; 166: 176–180.
35. Kahn SR, Shrier I, Julian JA, et al. Determinants and time course of the post-thrombotic syndrome after acute deep venous thrombosis. *Ann Intern Med* 2008; 149: 698–707.
36. Klok FA, Tijmensen JE, Haecck ML, et al. Persistent dyspnea complaints at long-term follow-up after an episode of acute pulmonary embolism: results of a questionnaire. *Eur J Intern Med* 2008; 19: 625–629.
37. Le Gal G, Kovacs MJ, Carrier M, et al. Validation of a diagnostic approach to exclude recurrent venous thromboembolism. *J Thromb Haemost* 2009; 7: 752–759.
38. Prandoni P, Noventa F, Ghirarduzzi A, et al. The risk of recurrent venous thromboembolism after discontinuing anticoagulation in patients with acute proximal deep vein thrombosis or pulmonary embolism. A prospective cohort study in 1,626 patients. *Haematologica* 2007; 92: 199–205.
39. Prandoni P, Lensing AW, Bernardi E, et al. The diagnostic value of compression ultrasonography in patients with suspected recurrent deep vein thrombosis. *Thromb Haemost* 2002; 88: 402–406.
40. Linkins LA, Stretton R, Probyn L, et al. Interobserver agreement on ultrasound measurements of residual vein diameter, thrombus echogenicity and Doppler venous flow in patients with previous venous thrombosis. *Thromb Res* 2006; 117: 241–247.
41. Westerbeek RE, Van Rooden CJ, Tan M, et al. Magnetic resonance direct thrombus imaging of the evolution of acute deep vein thrombosis of the leg. *J Thromb Haemost* 2008; 6: 1087–1092.
42. Tan M, Mol GC, van Rooden CJ, et al. Magnetic resonance direct thrombus imaging differentiates acute recurrent ipsilateral deep vein thrombosis from residual thrombosis. *Blood* 2014; 124: 623–627.
43. van Langevelde K, Tan M, Sramek A, et al. Magnetic resonance imaging and computed tomography developments in imaging of venous thromboembolism. *J Magn Reson Imaging* 2010; 32: 1302–1312.
44. Stein PD, Matta F. Noninvasive imaging in pulmonary embolism according to age and gender. *Clin Appl Thromb Hemost* 2014; 20: 143–146.
45. Carrier M, Righini M, Wells PS, et al. Subsegmental pulmonary embolism diagnosed by computed tomography: incidence and clinical implications. A systematic review and meta-analysis of the management outcome studies. *J Thromb Haemost* 2010; 8: 1716–1722.
46. Stein PD, Fowler SE, Goodman LR, et al. Multidetector computed tomography for acute pulmonary embolism. *N Engl J Med* 2006; 354: 2317–2327.
47. Wiener RS, Schwartz LM, Woloshin S. Time trends in pulmonary embolism in the United States: evidence of overdiagnosis. *Arch Intern Med* 2011; 171: 831–837.
48. Carrier M, Kimpton M, Le Gal G, et al. The management of a sub-segmental pulmonary embolism: a cross-sectional survey of Canadian thrombosis physicians. *J Thromb Haemost* 2011; 9: 1412–1415.
49. den Exter PL, van Es J, Klok FA, et al. Risk profile and clinical outcome of symptomatic subsegmental acute pulmonary embolism. *Blood* 2013; 122: 1144–1149; quiz 1329.
50. Carrier M, Righini M, Le Gal G. Symptomatic subsegmental pulmonary embolism: what is the next step? *J Thromb Haemost* 2012; 10: 1486–1490.
51. Remy-Jardin M, Pistolesi M, Goodman LR, et al. Management of suspected acute pulmonary embolism in the era of CT angiography: a statement from the Fleischner Society. *Radiology* 2007; 245: 315–329.
52. Righini M, Paris S, Le Gal G, et al. Clinical relevance of distal deep vein thrombosis. *Thromb Haemost* 2006; 95: 56–64.
53. Bernardi E, Camporese G, Buller HR, et al. Serial 2-point ultrasonography plus D-dimer vs whole-leg color-coded Doppler ultrasonography for diagnosing sus-

- pected symptomatic deep vein thrombosis: a randomized controlled trial. *J Am Med Assoc* 2008; 300: 1653–1659.
54. The PIOPED Investigators. Value of the ventilation/perfusion scan in acute pulmonary embolism. Results of the prospective investigation of pulmonary embolism diagnosis (PIOPED). *J Am Med Assoc* 1990; 263: 2753–2759.
 55. Le Duc-Pennec A, Le Roux PY, Cornily JC, et al. Diagnostic accuracy of single-photon emission tomography ventilation/perfusion lung scan in the diagnosis of pulmonary embolism. *Chest* 2012; 141: 381–387.
 56. Revel MP, Sanchez O, Couchon S, et al. Diagnostic accuracy of magnetic resonance imaging for an acute pulmonary embolism: results of the 'IRM-EP' study. *J Thromb Haemost* 2012; 10: 743–750.
 57. Stein PD, Chenevert TL, Fowler SE, et al. Gadolinium-enhanced magnetic resonance angiography for pulmonary embolism: a multicenter prospective study (PIOPED III). *Ann Intern Med* 2010; 152: 434–443, W142–143.
 58. Wicki J, Perneger TV, Junod AF, Bounameaux H, Perrier A. Assessing clinical probability of pulmonary embolism in the emergency ward: a simple score. *Arch Intern Med* 2001; 161: 92–97.
 59. Le Gal G, Righini M, Roy P-M, et al. Prediction of Pulmonary Embolism in the Emergency Department: The Revised Geneva Score. *Ann Intern Med* 2006; 144: 165–171.
 60. Wells PS, Anderson DR, Rodger M, et al. Derivation of a simple clinical model to categorize patients probability of pulmonary embolism: increasing the models utility with the SimpliRED D-dimer. *Thromb Haemost* 2000; 83: 416–420.
 61. Miniati M, Monti S, Bauleo C, et al. A diagnostic strategy for pulmonary embolism based on standardised pretest probability and perfusion lung scanning: a management study. *Eur J Nucl Med Mol Imaging* 2003; 30: 1450–1456.
 62. Miniati M, Monti S, Bottai M. A structured clinical model for predicting the probability of pulmonary embolism. *Am J Med* 2003; 114: 173–179.
 63. Kline JA, Nelson RD, Jackson RE, et al. Criteria for the safe use of D-dimer testing in emergency department patients with suspected pulmonary embolism: a multicenter US study. *Ann Emerg Med* 2002; 39: 144–152.
 64. Klok FA, Mos IC, Nijkeuter M, et al. Simplification of the revised Geneva score for assessing clinical probability of pulmonary embolism. *Arch Intern Med* 2008; 168: 2131–2136.
 65. Gibson NS, Sohne M, Kruij MJ, et al. Further validation and simplification of the Wells clinical decision rule in pulmonary embolism. *Thromb Haemost* 2008; 99: 229–234.